

Rickettsioses in the central hills of Sri Lanka: serological evidence of increasing burden of spotted fever group



S.A.M. Kularatne^a, R.P.V.J. Rajapakse^b, W.M.R.S. Wickramasinghe^a, D.M. Nanayakkara^b, S.S. Budagoda^a, K.G.A.D. Weerakoon^{c,*}, J.S. Edirisinghe^c, R. Premaratna^d

^a Department of Medicine, Faculty of Medicine, University of Peradeniya, Kandy, Sri Lanka

^b Department of Veterinary Pathobiology, Faculty of Veterinary Medicine and Animal Science, University of Peradeniya, Sri Lanka

^c Department of Parasitology, Faculty of Medicine and Allied Sciences, Rajarata University of Sri Lanka, Saliyapura, Anuradhapura, Sri Lanka

^d Department of Medicine, Faculty of Medicine, University of Kelaniya, Ragama, Sri Lanka

ARTICLE INFO

Article history:

Received 27 November 2012

Received in revised form 31 March 2013

Accepted 30 May 2013

Corresponding Editor: Eskild Petersen, Aarhus, Denmark

Keywords:

Rickettsial infections

Spotted fever group rickettsiae

Orientia tsutsugamushi

Rickettsia typhi

Vasculitis

Sri Lanka

SUMMARY

Objectives: To study the epidemiology, clinical features, and changing pattern of rickettsial infections on the western slopes of the hilly Central Province of Sri Lanka over 6 years.

Methods: All patients with rickettsial infections who presented to the Teaching Hospital, Peradeniya were studied prospectively from January 2002 to December 2007. An immunofluorescent antibody assay (IFA) was used to confirm the diagnosis.

Results: Of the 371 clinical cases of rickettsial infection, 122 underwent IFA to confirm the diagnosis. Species-specific IgG antibodies were positive in 105/122 (86.1%) cases: 43/105 (40.9%) to *Rickettsia conorii* and 6/105 (5.7%) to *Orientia tsutsugamushi*, with mixed antibody reactivity to more than one antigen in 56/105 (53.3%) cases, including *Rickettsia typhi* in 27/105 (25.7%). Among those with mixed IgG reactivity, IgM assays were used to detect pathogens responsible for acute infections. Finally, a total of 55 spotted fever group (SFG) infections, seven scrub typhus infections, and one case of murine typhus were identified. Of the 105 positive cases, 53 (50.5%) were male and 52 (49.5%) were female, and the mean age was 40 years (range 11–83 years). In the SFG patients, 13/55 (24%) had severe vasculitis with fern leaf type skin necrosis and 17/55 (31%) had arthritis. Three patients (5%) had an altered level of consciousness. A patient with scrub typhus had transient deafness. None of the 105 patients had an eschar.

Conclusions: It appears that SFG rickettsioses are on the rise in the hilly Central Province of Sri Lanka, whilst murine typhus and scrub typhus are present at a lower rate.

© 2013 International Society for Infectious Diseases. Published by Elsevier Ltd. All rights reserved.

1. Introduction

The very first recorded reference to rickettsial infections in Sri Lanka dates back to the period 1937–1945, the time of the Second World War, during which massive military efforts were made in the Eastern Province. It was during the same period that scrub typhus was detected in the southern coastal regions of the island.¹

A hospital-based study carried out in 2001² at the Teaching Hospital, Peradeniya (THP), described the prevalence of spotted fever group rickettsiae (SFG), *Orientia tsutsugamushi* and *Rickettsia typhi*, for the first time in the hilly Central Province of Sri Lanka. A later study conducted in the low-lying Western Province of the island, highlighted the predominance of *O. tsutsugamushi*

infection associated with pathognomonic eschars and deafness.^{3,4} In all these studies, the diagnosis was confirmed serologically by indirect immunofluorescent antibody assay (IFA). However, the IFA test does not differentiate infection within the SFG rickettsioses.⁵

Rickettsiae and rickettsial infections have become prevalent around the globe, creating a complex web; however there is a dearth of knowledge on responsible species, vectors, and their vertebrate hosts. New human rickettsial pathogens are increasingly recognized and their pathophysiological mechanisms are being determined in countries where facilities are available.⁶ However, in countries like Sri Lanka, where resources such as molecular diagnostic facilities are poor, the process of identifying new pathogens, vectors, and reservoirs is a daunting task. Nevertheless, research should be continued to understand more about rickettsioses in Sri Lanka. The cornerstone of such research would be extended or longitudinal epidemiological and clinical studies.

* Corresponding author. Tel.: +94 252226388, +94 776489375.

E-mail address: kosalagadw83@gmail.com (K.G.A.D. Weerakoon).

In order to fulfill these needs, we have maintained a database of all clinically diagnosed cases of rickettsial infection at the THP in the Central Province of Sri Lanka. In addition, serum samples of patients have been preserved for use in further studies.

The specific objectives of this study were to carry out hospital-based rickettsial disease surveillance in order to: (1) document all new cases, (2) assess the disease burden, (3) identify causative rickettsial species, (4) determine the trends in the incidence, (5) document their clinical presentations, and (6) to map out the geographical areas with high prevalence on the western slopes of the hilly Central Province of Sri Lanka.

2. Methods

2.1. Study population

All patients with clinically diagnosed rickettsial infections admitted to the Professorial Medical Unit of the THP during the period January 2002 to December 2007 were included in the study. Informed verbal consent was obtained from patients to record their clinical details for the study. Whenever photographs were taken, written consent was obtained for publication. The clinical case definition was based on fulfilling any two of the following criteria: fever for more than 5 days, erythematous discrete maculopapular rash, and rapid defervescence with an anti-rickettsial antibiotic (chloramphenicol or doxycycline). A total of 371 patients fulfilled the above criteria. Demographic and clinical details of each patient were recorded on separate data sheets. The basic demographic data collected were age, gender, residence, information on socio-economic status, and history of contact with animals and arthropod bites. In addition, all the symptoms and signs of these patients were recorded. A sketch of a human figure was included in the questionnaire to highlight the location of the skin rash on the body. Efforts were made to locate the eschar and to detect skin necrosis in each patient. Clinical signs and symptoms were assessed daily and the response to treatment was documented. Routine investigations such as white blood cell count and differential count (WBC–DC), hemoglobin (Hb%), platelet count, erythrocyte sedimentation rate (ESR), alanine transaminase (ALT), and aspartate transaminase (AST) were carried out.

2.2. Indirect immunofluorescent antibody assay (IFA)

At the time of blood sample collection for the assay, all patients had been on the hospital ward for at least 1 week. Thus, serological results were obtained from single/daily blood samples taken during the illness. From each patient, a 5-ml venous blood sample was collected into a plain tube and allowed to clot at room temperature. The samples were centrifuged at $2500 \times g$ for 10 min and the sera were stored at -40°C prior to testing. A batch of 122 serum samples was randomly selected from the total of 371 cases for IFA testing. This was due to limitations in facilities for the performance of IFA tests at the local laboratory. IFA was used for the determination of IgG and IgM antibody titers against prototype strains of *O. tsutsugamushi* (serotype Karp), *R. typhi* (Wilmington), and *Rickettsia conorii* (Malish) antigens. Teflon-coated IFA slides (Cell-line, Erie Scientific Co.) with 32 wells were used for antigen coating. Specific rickettsial antigens were obtained from the World Health Organization Reference Center for Rickettsial and Bartonella Associated diseases, CDC, Atlanta, USA.

Antibodies were detected using fluorescein-conjugated goat anti-human IgG (γ -chain) or IgM (μ -chain) (KPL, Inc., Gaithersburg, MD, USA). Sera were screened at 1/32 dilution, and positive samples were titered to the endpoint using a two-fold dilution series. In this study, an IFA titer of 1:256 was considered positive

for a definite diagnosis. However, any positive IgG reactivity only with a target antigen was taken as an antibody-positive case.

The final diagnosis of rickettsial infection was defined on the basis of clinical criteria and the presence of specific IFA IgM and IgG seroreactivity.^{2,3,7,8} Serological evidence with high antibody titers in acute serum samples alone has been considered confirmative in certain previous studies.^{7,8} Premaratna et al., in 2012, attempted to determine a clinically helpful diagnostic algorithm, and showed that if the acute serum sample was obtained after 7 days of the illness, a single IgG titer of 1/256 could be considered diagnostic, with the presence of supportive clinical evidence.⁹

3. Results

3.1. Epidemiology of rickettsial infections in the central hills

Figures 1 and 2 show the annual distribution of clinical cases ($n = 371$) and their bimonthly distribution, reflecting the seasonal occurrence of cases. All patients presented as sporadic cases throughout the year without any seasonal preponderance. Patients were residents of the Central Province of Sri Lanka, living along a stretch of land with hills and valleys of approximately 50 km, located between Nawalapitiya in the north and Kegalle in the south, on the western slopes. The area varies from being semi-urban to rural, where lush high-growing evergreen vegetation is interspersed with the human dwellings. The majority of the patients belonged to the middle or lower socio-economic class and most kept domestic animals. Of the wild animals, the wild boar in

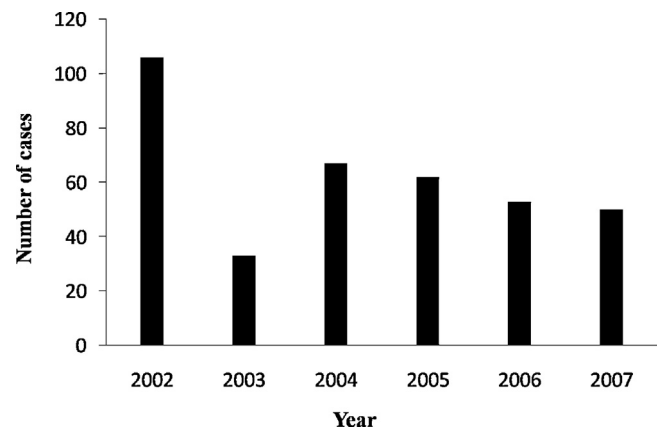


Figure 1. Annual distribution of clinical cases of rickettsioses over 6 years ($n = 371$).

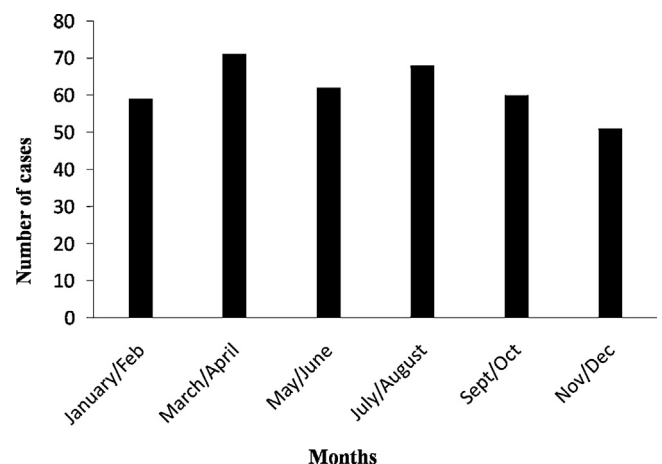


Figure 2. Monthly distribution of clinical cases of rickettsioses ($n = 371$).

Table 1
Detection of IgG antibody titers in acute serum of 105 patients tested for three antigens

Titer level	<i>R. conorii</i> (RC)		<i>O. tsutsugamushi</i> (OT)		<i>R. typhi</i> (RT)	
	Sera reacting with RC antigen only (n=43) n (%)	Sera reacting with RC and other antigens (n=62) n (%)	Sera reacting with OT antigen only (n=6) n (%)	Sera reacting with OT and other antigens (n=99) n (%)	Sera reacting with RT antigen only (n=0) n (%)	Sera reacting with RT and other antigens (n=105) n (%)
<1/32	5 (11.6)	17 (27.4)	5 (83.3)	89 (89.9)	0	86 (81.9)
1/32	2 (4.7)	1 (1.6)	1 (16.7)	4 (4.0)	0	0
1/64	2 (4.7)	3 (4.8)	0	3 (3.0)	0	0
1/128	5 (11.6)	4 (6.4)	0	1 (1.0)	0	5 (4.8)
1/256	4 (9.3)	4 (6.4)	0	1 (1.0)	0	5 (4.8)
1/512	5 (11.6)	4 (6.4)	0	0	0	3 (2.9)
1/1024	6 (14.0)	5 (8.1)	0	0	0	3 (2.9)
1/2048	5 (11.6)	8 (12.9)	0	1 (1.0)	0	3 (2.9)
1/4096	9 (20.9)	16 (25.8)	0	0	0	0

Table 2
Type of rickettsial infection identified in 122 clinical cases, based on IFA

Serodiagnosis/exposure agent	IgG titer \geq 1/256		IgM reactivity ^a	Total seroreactive status
	Target antigen	Multiple antigen		
SFG rickettsiosis	29	37	26	55
Scrub typhus	0	2	7	7
Murine typhus	0	14	1	1
Undetermined rickettsial etiology ^b	0	56 ^a	0	22
No rickettsial reaction	17		22 ^c	17

IFA, immunofluorescent antibody assay; SFG, spotted fever group.

^a Fifty-six sera with multiple IgG reactivity were further tested for IgM to detect acute infections.

^b Mixed infection or acute infection and pre-existing antibodies.

^c Twenty-two were IgM-negative but had multiple IgG reactivity.

particular was noted in increasing numbers in the region and was frequently found roaming around the home gardens at night. We identified 14 hot pockets of rickettsial infection in this region, all of which were rural villages, where road access was difficult due to the hilly terrain.

Table 3
Clinical details of patients categorized into three rickettsial infections^a

Parameter	Number of patients (n)		
	SFG (n=55)	Scrub typhus (n=7)	Murine typhus (n=1)
Age, years, mean (range)	41 (11–83)	40 (15–67)	23
Gender, male:female	28:27	5:2	Male
Prodrome	17 (31)	3 (43)	0
Fever	54 (98)	7 (100)	1
Headache	43 (78)	6 (86)	0
Skin rash	39 (71)	4 (57)	1
Fern leaf skin necrosis	13 (24)	0	0
Myalgia	42 (76)	6 (86)	0
Nausea	28 (51)	3 (43)	0
Vomiting	22 (40)	3 (43)	0
Abdominal pain	8 (15)	1 (14)	0
Watery diarrhea	8 (13)	1 (14)	0
Cough	14 (25)	1 (14)	1
Deafness	0	1 (14)	0
Tinnitus	11 (20)	1 (14)	0
Arthritis	17 (31)	0	0
Icterus	9 (16)	0	0
Conjunctival injection	14 (25)	2 (29)	0
Enlarged liver	24 (44)	2 (29)	0
Enlarged spleen	5 (9)	0	0
Confusion	3 (5)	0	1
Hallucinations	1 (2)	0	0
Insect (?tick) bite	14 (25)	3 (42)	1

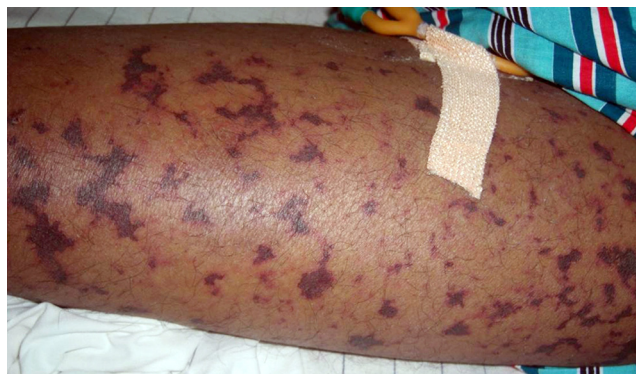^a Results are n (%), unless otherwise stated.

3.2. Serology

The IgG and IgM titers to the three rickettsial agents and the types of rickettsial infection identified are shown in [Tables 1 and 2](#). Rickettsia-specific IgG (gamma-specific) antibodies were positive in 105/122 (86.1%) of the suspected cases: 43/105 (40.9%) for *R. conorii* and 6/105 (5.7%) for *O. tsutsugamushi*, with 56/105 (53.3%) of mixed antibody reactivity, in which the titer of *R. typhi* was present in 27/105 (25.7%). A total of 55 spotted fever cases, seven scrub typhus infections, and one murine typhus case were identified by differentiation of mixed cases with IgM assays. Titers of IgG $>$ 1/256 were detected for *R. conorii* (29 *R. conorii* only and 37 cross-reactivity with other antigens), whilst in 14 cases antibodies to *R. typhi* were detected at the same time as reactivity to other antigens tested.

3.3. Clinical manifestations

Of the 105 patients who were serologically positive for Rickettsia IgG antibodies, 53/105 (50.5%) were male and 52/105 (49.5%) were female, and their mean age was 40 years (range 11–83 years). Most of the clinical features were common to all of the patients ([Table 3](#)). In the SFG infection patients, 13/55 (24%) had life-threatening severe vasculitis with fern leaf type skin necrosis ([Figure 3](#)) and 17/55 (31%) had arthritis ([Figure 4](#)). Three patients (5%) had altered levels of consciousness. These patients required administration of intravenous corticosteroids in addition to intravenous chloramphenicol for clinical recovery. Scrub typhus infections were mild, but one patient had transient deafness. None of the 105 patients had eschars, but 14/55 (25%) SFG patients had a history of tick bite prior to the onset of fever. Thirty-nine SFG

**Figure 3.** Severe vasculitis with fern leaf type skin necrosis in a spotted fever patient.

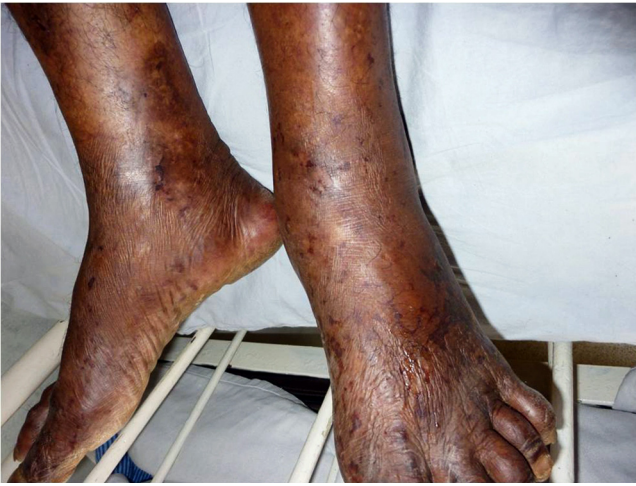

Figure 4. Acute arthritis involving ankle joints in spotted fever.

patients (71%) had a maculopapular rash distributed mainly on the limbs, including palms and soles (Figure 5, Table 3). Of the clinical cases for whom IFA assays were not done, three died of their illness due to a delay in diagnosis and in starting appropriate treatment. All three had extensive vasculitis with fern leaf skin necrosis and later developed irreversible multi-organ failure. The patient with murine typhus had a milder form of infection, but had transient confusion. Of the serologically confirmed group (Table 3), 43/63 (68%) had fever and a skin rash, 62/63 (98%) had fever with a response to antibiotic treatment, and 44/63 (70%) had a skin rash with a response to antibiotic treatment.

4. Discussion

Continued surveillance from 2002 over a period of 6 years, at a sentinel hospital in the hilly Central Province of Sri Lanka, detected a substantial number of rickettsial infections diagnosed clinically and confirmed with serology (IFA). The IFA assay was positive for antigens of *R. conorii*, *O. tsutsugamushi*, or *R. typhi*. All cases had positive IgG titers for *R. conorii*, suggesting a predominance of SFG rickettsioses in this hilly rural setting. In contrast, scrub typhus occurred at a low rate in the region, and murine typhus was detected rarely. Even though *R. typhi* was used as a testing antigen, the results do not exclude the presence of or exposure to *Rickettsia felis* in this region, as found elsewhere in the world.^{10,11}

For the IFA assays we used antigens of *R. conorii*, a member of the SFG rickettsiae, prevalent in southern Europe, in many parts of Africa, and in Asia. However, this organism has a wide antigenic

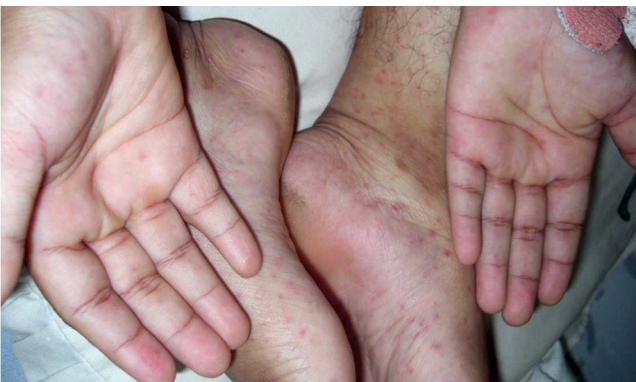

Figure 5. Discrete erythematous maculopapular rash involving palms and soles in SFG rickettsial infections.

diversity thought to be due to a longer period of evolutionary divergence.¹² Furthermore, a pathogenic *R. conorii* subspecies *indica*, identified in India, appears to cause rickettsial illness with clinical manifestations different from classic Mediterranean spotted fever.^{13,14} Thus, the use of *R. conorii* antigen seems to be logical in Sri Lanka in the initial diagnosis of SFG rickettsioses. However, further characterization of the organism using more advanced methods is warranted in order to identify the local strain(s) of SFG rickettsioses responsible for the infection in Sri Lanka. A difference exists in the studies conducted in the Western Province of Sri Lanka, where a low prevalence of SFG has been documented compared to infection by *O. tsutsugamushi*.³

Our study found the continuous occurrence of rickettsial infections in an endemic fashion in the regions where hot pockets of infection have been identified along the extended rickettsial belt in the central hills of Sri Lanka. In contrast to the first study carried out from 2000 to 2001 in the same region, in which the SFG rate was 35%, the current study found a SFG rate of 66%, showing the predominance of SFG.² An enhanced active surveillance and improvements in clinical recognition of these diseases may have contributed to the detection of more cases.

Clinically, SFG rickettsioses showed a severe disease condition, similar to a previous report describing the clinical features of 21 cases.² However, in this series, a few patients with SFG rickettsioses suffering from confusion and hallucinations were detected for the first time. The absence of eschar and the presence of a fern leaf necrotic skin rash in very severe SFG cases were findings similar to those of the previous report.² A similar clinical picture has been described for Rocky Mountain spotted fever (RMSF) caused by *Rickettsia rickettsii*, in which eschar was absent whilst skin necrosis and cerebral manifestations could occur.^{15–18} In contrast, patients suffering from Mediterranean spotted fever caused by *R. conorii* present with an eschar, but often experience a less severe illness without necrotic skin rashes.⁵ These findings thus arouse curiosity as to which rickettsial agent is responsible for SFG rickettsioses in Sri Lanka. One way to overcome this would be to isolate and identify the pathogen, similar to the recent isolation of *Rickettsia akari* from eschars and skin rashes of patients with rickettsialpox in America.^{19–21} The etiological agents responsible for SFG infections are currently being studied in Sri Lanka.

It is likely that the prevailing environmental conditions and host or vector factors are more suited to the spread of SFG in the central hills of Sri Lanka. Approximately 14 (20%) SFG patients in this series had tick bites prior to their illness. A similar rate has been recorded for 16 cases of RMSF, where the common brown dog tick (*Rhipicephalus sanguineus*) was the vector.¹⁷ We assume either dog ticks or ticks on wild pigs to be the possible vectors of SFG in the study region of the Central Province of Sri Lanka. However, transmission of rickettsial agents via flea or mite bites cannot be ruled out at this point. Studies are currently being directed towards finding answers to these questions.

Past exposure to more than one rickettsial agent may be the cause of the high prevalence of mixed multiple antibodies in this series. Moreover, of the three antigenic groups, cross-reactions between SFG and typhus group have been reported.²² Hence cross-reactivity of rickettsial antigen may also be a possibility.

The results of the current study confirm the presence of murine typhus (*R. typhi*), scrub typhus (*O. tsutsugamushi*), and SFG in the central hills of Sri Lanka. However, the burden of disease due to SFG rickettsiosis is far greater than that of the other rickettsial infections in this region.

Acknowledgements

The authors thank Prof. S.N. Arsecularatne for his valuable comments on the manuscript.

Ethical approval: This study is a part of the rickettsial studies we are carrying out, for which ethical approval has been obtained from the Ethics Committee, Faculty of Medicine, Peradeniya University, Sri Lanka.

Conflict of interest: The authors declare that they have no competing interests.

References

- Edirisinghe JS, Kularatne SA. Rickettsioses in Sri Lanka. In: Yano A, Nam HW, editors. *Asian parasitology*. Chiba, Japan: The Federation of Asian Parasitologists; 2005. p. 262–76.
- Kularatne SA, Edirisinghe JS, Gawarammana IB, Urakami H, Chenchittikul M, Kioho I. Emerging rickettsial infections in Sri Lanka: the pattern in the hilly Central Province. *Trop Med Int Health* 2003;**8**:803–11.
- Premaratna R, Loftis AD, Chandrasena TG, Dash GA, de Silva HJ. Rickettsial infections and their clinical presentations in the Western Province of Sri Lanka: a hospital-based study. *Int J Infect Dis* 2008;**12**:198–202.
- Premaratna R, Chandrasena TG, Dassanayaka AS, Loftis AD, Dash GA, de Silva HJ. Acute hearing loss due to scrub typhus: a forgotten complication of a re-emerging disease. *Clin Infect Dis* 2006;**42**:6–8.
- Raoult D, Roux V. Rickettsioses as paradigms of new or emerging infectious diseases. *Clin Microbiol Rev* 1997;**10**:694–719.
- Walker DH. Rickettsiae and rickettsial infections: the current state of the knowledge. *Clin Infect Dis* 2007;**45**:39–44.
- Premaratna R, Rajapakse RP, Chandrasena TG, Nanayakkara DM, Bandara NK, Kularatna SA, et al. Contribution of rickettsioses in Sri Lankan patients with fever who responded to empirical doxycycline treatment. *Trans R Soc Trop Med Hyg* 2010;**104**:368–70.
- Liyanaathirana VC, Thevanesam V. Seroepidemiology of rickettsioses in Sri Lanka: a patient based study. *BMC Infect Dis* 2011;**11**:328.
- Premaratna R, Weerasinghe S, Ranaweera A, Chandrasena TN, Bandara NW, Dasch GA, et al. Clinically helpful rickettsial disease diagnostic IgG titers in relation to duration of illness in an endemic setting in Sri Lanka. *BMC Res Notes* 2012;**30**:662.
- Pérez-Osorio CE, Zavala-Velázquez JE, Arias León JJ, Zavala-Castro JE. *Rickettsia felis* as emergent global threat for humans. *Emerg Infect Dis* 2008;**14**:1019–23.
- Reif KE, Macaluso KR. Ecology of *Rickettsia felis*: a review. *J Med Entomol* 2009;**46**:723–36.
- Walker DH, Liu QH, Yu XJ, Li H, Taylor C, Feng HM. Antigenic diversity of *Rickettsia conorii*. *Am J Trop Med Hyg* 1992;**47**:78–86.
- Zhu Y, Fournier PE, Ereemeeva M, Raoult D. Proposal to create subspecies of *Rickettsia conorii* based on multi-locus sequence typing and an emended description of *Rickettsia conorii*. *BMC Microbiol* 2005;**14**:5–11.
- Parola P, Fenollar F, Badiaga S, Brouqui P, Raoult D. First documentation of *Rickettsia conorii* infection (strain Indian tick typhus) in a traveler. *Emerg Infect Dis* 2001;**7**:909–10.
- Dantas-Torres F. Rocky Mountain spotted fever. *Lancet Infect Dis* 2007;**7**:724–32.
- Buckingham SC, Marshall GS, Schutze GE, Woods CR, Jackson MA, Patterson LE, et al. Clinical and laboratory features, hospital course, and outcome of Rocky Mountain spotted fever in children. *J Pediatr* 2007;**150**:180–4.
- Angerami RN, Resende MR, Feltrin AF, Katz G, Nascimento EM, Stucchi RS, et al. Brazilian spotted fever: a case series from an endemic area in southeastern Brazil: clinical aspects. *Ann N Y Acad Sci* 2006;**1078**:252–4.
- Dahlgren FS, Holman RC, Paddock CD, Callinan LS, McQuiston JH. Fatal Rocky Mountain spotted fever in the United States, 1999–2007. *Am J Trop Med Hyg* 2012;**86**:713–9.
- Paddock CD, Koss T, Ereemeeva ME. Isolation of *Rickettsia akari* from eschars of patients with rickettsialpox. *Am J Trop Med Hyg* 2006;**75**:732–8.
- Cragun WC, Bartlett BL, Ellis MW, Hoover AZ, Tying SK, Mendoza N, et al. The expanding spectrum of eschar-associated rickettsioses in the United States. *Arch Dermatol* 2010;**146**:641–8.
- Spolidorio MG, Labruna MB, Mantovani E, Brandao PE, Richtzenhain LJ, Yoshinari NH. Novel spotted fever group rickettsiosis, Brazil. *Emerg Infect Dis* 2010;**16**:521–3.
- Tissot-Dupont H, Brouqui P, Faugere B, Raoult D. Prevalence of antibodies to *Coxiella burnetii*, *Rickettsia conorii* and *Rickettsia typhi* in seven African countries. *Clin Infect Dis* 1995;**21**:1126–33.